

Research Article

Received Date: May 01, 2024

Accepted Date: June 01, 2024

Published Date: June 04, 2024

\*Corresponding Author

Xia Qingfu, Spine Surgery, Beijing Dawang Lu Emergency Hospital, Beijing 100122, China, Tel: 13651186277, E-mail: xiaqingfu16888@163.com.

Citation

Yang Yunfei, Huang Lijun, Xia Qingfu, Zhang Yushuang, Zhao Guofeng, et al. (2024) The Clinical Effect Modified Halo-Pelvic Traction in the Patients with Severe Spinal Deformity Accompanied by Respiratory Disorder. CEOS Orthop Rheumatol 2(1): 102

Copyrights@Xia Qingfu

## The Clinical Effect Modified Halo-Pelvic Traction in the Patients with Severe Spinal Deformity Accompanied by Respiratory Disorder

Yang Yunfei<sup>1</sup>, Huang Lijun<sup>1</sup>, Xia Qingfu<sup>1\*</sup>, Zhang Yushuang<sup>2</sup>, Zhao Guofeng<sup>2</sup>, Xia Jiyuan<sup>3</sup>, Tian Xinqi<sup>2</sup> and Liu Chang<sup>2</sup>

<sup>1</sup>Spine Surgery, Beijing Dawang Lu Emergency Hospital, Beijing 100122, China

<sup>2</sup>Spine Surgery, Beijing Youlian Hospital, Beijing 100023, China

<sup>3</sup>Clinical medicine, Hebei Medical University, Shijiazhuang, Hebei 050011, China

### Abstract

**Objective:** To explore the clinical effect of one-staged modified Halo-pelvic traction combined with two-stage surgery for severe spinal deformity accompanied by respiratory disorder.

**Methods:** From January 2019 to January 2022, a total of 120 patients with severe spinal deformity accompanied by respiratory disorder were enrolled at Beijing Da Wang Lu Emergency Hospital. All patients underwent modified Halo-pelvic traction followed by surgical correction. The changes of imaging and respiratory function indicators were compared at pre-traction, post-traction, post-operative and the last follow-up.

**Results:** At pre-traction, the levels of main curve Cobb angle, C7 plumb Line-center sacral vertical line (C7PL-CSVL), apical vertebral translation (AVT), T1 tilt angle, radiographic shoulder height, sagittal vertical axis (SVA), thoracic kyphosis (TK) were (119.17±15.39)°, (33.33±7.2)mm, (103.55±16.56)mm, (20.13±5.94)°, (26.78±6.32)mm, (38.29±5.54)mm, (87.66±11.63)°, higher than at post-traction [(74.62±15.15)°, (13.23±4.27)mm, (57.70±17.56)mm, (9.29±1.73)°, (10.18±2.00)mm, (14.41±3.24)mm, (52.96±12.11)°], post-operative [(60.78±14.40)°, (12.42±3.58)mm, (44.31±13.77)mm, (8.89±2.66)°, (9.38±2.39)mm, (17.11±3.24)mm, (51.28±11.20)°] and last follow-up [(64.21±14.86)°, (12.69±3.26)mm, (45.17±11.65)mm, (6.51±1.77)°, (9.53±2.36)mm, (17.50±3.07)mm, (51.82±12.20)°], the difference was statistically significant ( $P<0.01$ ). At pre-traction, the levels of FVC, FVC%, FEV1, FEV1% were (1.13±0.19)L, (31.61±4.64)%, (1.08±0.22)L, (29.68±11.56)%, lower than at post-traction [(1.36±0.28)L, (36.19±4.95)%, (1.17±0.19)L, (33.45±5.97)%]; post-operative [(1.49±0.28)L, (38.08±7.46)%, (1.26±0.22)L, (35.91±7.81)%] and the last follow-up [(1.53±0.26)L, (38.61±6.91)%, (1.28±0.24)L, (36.88±7.85)%], the difference was statistically significant ( $P<0.01$ ).

**Conclusion:** Modified Halo-pelvic traction can effectively correct spinal deformity of patients with severe spinal deformity accompanied by respiratory disorder, improving the respiratory function; it is a safe and effective adjuvant treatment measure.

**Keywords:** Halo-Pelvic Traction; Modified; Respiration Disorder; Severe Spinal Deformity

## Introduction

Spinal deformities refer to deformities where the curvature of the spine is convex in the coronal plane, convex in the posterior plane, and convex in the sagittal plane. When the Cobb angle of the deformity is greater than 90°, it is called a severe deformity [1]. Severe spinal deformities are often accompanied by reduced thoracic volume, pulmonary parenchymal compression, restricted diaphragm activity, airway changes, obstructed lung ventilation, and decreased lung capacity, which in turn affect the patient's respiratory function [2]. A survey shows that the incidence of respiratory dysfunction in patients with severe spinal deformities is as high as 80%, which is the main cause of adverse events such as circulatory disorders, pulmonary hypertension, pulmonary heart disease, and even death [3]. There is still controversy in clinical practice regarding the treatment measures for patients with severe spinal deformities and respiratory dysfunction. In order to reduce the risk of surgical complications, most scholars advocate avoiding primary surgery and using adjuvant treatments such as traction to reduce spinal stiffness [4]. Currently, traction methods such as Halo femoral traction (HFT) and Halo gravity traction (HGT) are commonly used in clinical practice. HFT can provide strong traction and quickly improve spinal deformities in a short period of time, but this method greatly restricts patient activity, is not conducive to exercising cardiovascular function, and is prone to complications such as pressure injury and pneumoconiosis. It is only used for short-term preoperative traction [5]. HGT is a safe and effective traction method, but it provides less corrective force and has drawbacks such as low treatment efficiency and long treatment cycle [6]. Halo pelvic traction (HPT) has been used for the treatment of scoliosis patients since the 1970s. This method can provide strong traction around the clock and effectively correct various spinal deformities [7]. However, traditional HPT requires a full body traction frame, which affects patient comfort and sleep quality, limiting its clinical application [8]. In view of this, this study improved the HPT method and applied it to patients with severe spinal deformities and respiratory dysfunction to observe its safety and effectiveness, aiming to provide reference for the treatment of severe spinal deformities. The following report is presented.

## Materials and Methods

### General Information

Using a pre - and post experimental control design method, 120 patients with severe spinal deformities and respiratory dysfunction admitted to Beijing Dawang Road Emergency Rescue Hospital from January 2019 to January 2022 were selected as the study subjects. Inclusion criteria: ①No gender or age limit; ②Spinal X-ray shows a Cobb angle greater than 90° for main curvature and a Cobb angle greater than 125° for lateral curvature; ③Accompanied by respiratory dysfunction (partial pressure of carbon dioxide PaCO<sub>2</sub> ≥ 50mmHg, forced lung capacity FVC% < 60%); ④Choose the first stage of HPT treatment and the second stage of simple posterior column osteotomy correction+pedicle screw internal fixation surgery; ⑤The patient voluntarily accepts this treatment plan and signs an informed consent form. Exclusion criteria: ①Previous spinal surgery, including internal growth rod insertion, anterior release, revision surgery, etc.; ②There are contraindications for traction, such as spinal fractures, dislocations, etc.; ③Concomitant ankylosing spondylitis, spinal tumors, spinal tuberculosis, and other spinal diseases; ④There is skin damage at the puncture point, making it impossible to install the pelvic ring; ⑤Concomitant mental illness, unable to cooperate with HPT treatment. Exit criteria: ①Those who voluntarily give up during HPT treatment; ②Severe complications such as pneumothorax, severe atelectasis, cranial nerve injury, and lower limb paralysis may occur during the treatment process. This study was approved by the Medical Ethics Committee of Beijing Dawang Road Emergency Rescue Hospital.

## Method

### Improvement of HPT device characteristics

The application of traditional HPT in severe spinal deformities is relatively limited, mainly due to the following reasons: ①The traction frame is distributed around the trunk and fixed in position, which affects the patient's supine sleep posture and leads to poor patient tolerance [9] ②The pelvic ring

is a closed loop, which is inconvenient to wear due to significant differences in patient body size [10]. This study improves the traditional HPT traction device by using a pelvic ring as a half ring, which can be worn from the side, reducing the inconvenience caused by the closed-loop structure being worn from the foot; And place the traction rod on the front outer side of the patient, allowing them to sleep, dress, and move on their own while still achieving 24-hour uninterrupted traction.

### Improve the Installation and Traction Strategy of the HPT device

The HPT device consists of a head ring, pelvic ring, and a telescopic link. The number of screws inserted into the pelvis depends on the patient's bone condition and anatomical variation. All patients completed the installation of HPT devices under local anesthesia in a sterile operating room. The patient is placed in a supine position, and the standing position is confirmed to mark the insertion point. The skin near the insertion point is disinfected and covered with a cloth. Three 4.5mm or 5.5mm diameter iliac screws are prepared to be inserted into the top platform area between the bilateral anterior superior iliac spine and the posterior superior iliac spine. The depth is approximately 7cm according to the patient's iliac bone condition. Then place the head ring traction device and try to maintain a consistent distance between the surrounding gaps, with the traction rod placed on the front outer side of the patient. The traction frame was constructed within 3-5 days to facilitate the patient's full adaptation to the head ring and pelvic screws. After the framework construction is completed, traction treatment begins. In the first week, the spiral traction frame is extended at a speed of 0.5cm/d. Starting from the second week, adjust to 0.3-0.5cm/d and intermittently adjust the traction frame to avoid pain intolerance and nerve complications caused by repeated traction. Check the patient's cranial and limb nerves daily. Once neurological complications occur, such as numbness, weakness, tongue deviation, and difficulty swallowing, the traction should be stopped immediately, and the traction rod should be appropriately shortened. If necessary, the length before traction should be shortened, and symptomatic treatment should be combined. After the symptoms disappear, traction should be

given. Perform daily nail care to keep the skin near the nail path clean and dry, and avoid long-term retention that may cause local infections. Regularly check if the screws are loose or displaced. If the patient experiences pain around the nail path, it often indicates that the screws are loose and should be tightened in a timely manner. Review X-ray films every 3 weeks during the traction period.

### Surgical Plan

After the first stage of traction treatment, a posterior spinal scoliosis correction surgery was performed under selective general anesthesia, and HPT traction was maintained during the operation. The patient is placed in a prone position, and the screw at the head of the traction rod is loosened 3-5 cm upwards to fully expand and further correct spinal deformities during surgery. Post-operative support protection for 3 months, release the support immobilization according to the bone fusion situation, and adhere to rehabilitation exercise. Follow up with full length spinal X-ray at 3 months, 6 months, 12 months, and every 6 months thereafter.

## Observation Indicators

### Imaging Indicators

The imaging examinations were performed on a standing position X-ray of the entire length of the spine, with a follow-up every 3 weeks during traction. Collect data on the coronal and sagittal planes of the entire spine in the standard standing position before HPT traction, during the last traction follow-up, after internal fixation surgery (the first month after internal fixation surgery), and during the last follow-up. The specific indicators include: ①Cobb angle of the main curvature: the angle between the maximum angles of the two vertebral bodies that tilt the main curvature of the spine. ②C7 Plumb Line Center Sacral Vertical Line (C7PL-CSVL): The distance between the lead line at the midpoint of the C7 vertebral body. ③The midline of the sacrum Apical Vertebral Translation (AVT): The horizontal distance from the center of the main curvature of the vertebral body to the midline of the sacrum. ④T1 inclination angle: the angle between the upper endplate of the thoracic vertebral body and the horizontal

line. ©Imaging shoulder height: The height difference of soft tissue above the acromioclavicular joint. ©Sagittal vertical axis (SVA): The distance between the C7 vertical line and the upper angle of the S1 vertebral body. ©Thoracic kyphosis (TK): The angle between the upper endplate of the thoracic vertebrae and the lower endplate of the thoracic vertebrae.

### Pulmonary Function Test (PFT)

PFT was performed before HPT traction, at the last traction, before internal fixation surgery, and at the last follow-up. The observation indicators included forced vital capacity (FVC), the percentage of FVC measured and estimated values (FVC%), forced expiratory volume at 1 second (FEV1), and the percentage of FEV1 measured and estimated values (FEV1%). To ensure the accuracy and reliability of the data, PFT was tested three times and the average value was taken.

### Statistical Methods

Perform data analysis using SPSS 25.0 software. Quantitative data that conform to normal distribution are described as ( $\pm$  s), and one-way repeated measures analysis of variance is used to compare the differences in imaging indicators and lung function indicators before and after traction. Subsequently, pairwise comparisons are conducted using Bonferroni's test. Count data is expressed in frequency and percentage. In repeated measures ANOVA,  $P < 0.05$  indicates a statistically significant difference; In the Bonferroni test for multiple comparisons,  $P < 0.0125$  indicates a statistically significant difference.

## Results

### General Information of Patients

Among 120 patients who underwent HPT in the first phase, there were 40 males (33.3%) and 80 females (66.7%); 55 cases (45.8%) were mainly characterized by kyphosis, while 65 cases (54.2%) were mainly characterized by kyphosis; Age

12-55(32.34 $\pm$ 13.07) years old, traction time 5-15(9.68 $\pm$ 3.29)-weeks, follow-up time 7-30(19.00 $\pm$ 6.73)months.

All patients successfully completed the second stage simple posterior column osteotomy correction combined with pedicle screw internal fixation, including 63 cases of thoracoplasty (52.5%) and 57 cases of combined satellite rod technology (47.5%); the surgical time was 123-400 (288.18 $\pm$ 66.46) minutes, and the intraoperative bleeding volume was 300-790 (547.59 $\pm$ 146.43) ml. There were 7-17 (12.11 $\pm$ 3.12) fused segments, and the height before traction was 114-158 (135.28 $\pm$ 12.97) cm. After traction, the height was 130-165 (147.78 $\pm$ 10.94) cm.

### Comparison of Imaging Indicators Before and After Traction

Univariate repeated measures analysis of variance showed that there were statistically significant differences ( $P < 0.01$ ) in the Cobb angle, C7PL-CSVL, AVT, T1 tilt angle, shoulder height on imaging, SVA, TK and other indicators of the main curvature before traction, the last follow-up of traction, internal fixation surgery, and the last follow-up of HPT treatment. The Bonferroni pairwise comparison results showed that the imaging indicators of the patients before traction were significantly higher than those of the last traction follow-up, internal fixation surgery, and last follow-up ( $P < 0.01$ ). As shown in the Table 1.

Comparison of respiratory function indicators before and after traction. Univariate repeated measures analysis of variance showed that there were statistically significant differences ( $P < 0.01$ ) in FVC, FVC%, FEV1, FEV1%, and other indicators before traction, the last follow-up of traction, internal fixation surgery, and the last follow-up of HPT treatment. The Bonferroni pairwise comparison results showed that the respiratory function indicators before traction were significantly lower than those after the last traction follow-up, internal fixation surgery, and last follow-up ( $P < 0.01$ ). As shown in the Table 2 below.

**Table 1:** Comparison of imaging indicators before and after traction in 120 patients (±s)

index	Before traction	Final traction review	After internal fixation surgery	Last follow-up	F-value	P-value
Cobb angle of the main curvature	119.17±15.39	74.62±15.15 <sup>a</sup>	60.78±14.40 <sup>a</sup>	64.21±14.86 <sup>a</sup>	410.591	<0.001
C7PL-CSVL (mm)	33.33±7.21	13.23±4.27 <sup>a</sup>	12.42±3.58 <sup>a</sup>	12.69±3.26 <sup>a</sup>	547.127	<0.001
AVT (mm)	103.55±16.56	57.70±17.56 <sup>a</sup>	44.31±13.77 <sup>a</sup>	45.17±11.65 <sup>a</sup>	417.904	<0.001
T1 inclination angle (°)	20.13±5.94	9.29±1.73 <sup>a</sup>	8.89±2.66 <sup>a</sup>	6.51±1.77 <sup>a</sup>	397.152	<0.001
Imaging shoulder height (mm)	26.78±6.32	10.18±2.00 <sup>a</sup>	9.38±2.39 <sup>a</sup>	9.53±2.36 <sup>a</sup>	656.088	<0.001
SVA (mm)	38.29±5.54	14.41±3.24 <sup>a</sup>	17.11±3.24 <sup>a</sup>	17.50±3.07 <sup>a</sup>	968.566	<0.001
TK (°)	87.66±11.63	52.96±12.11 <sup>a</sup>	51.28±11.20 <sup>a</sup>	51.82±12.20 <sup>a</sup>	284.314	<0.001

Compared to before towing, <sup>a</sup>P<0.01°

**Table2:** Comparison of respiratory function indicators before and after traction in 120 patients (±s)

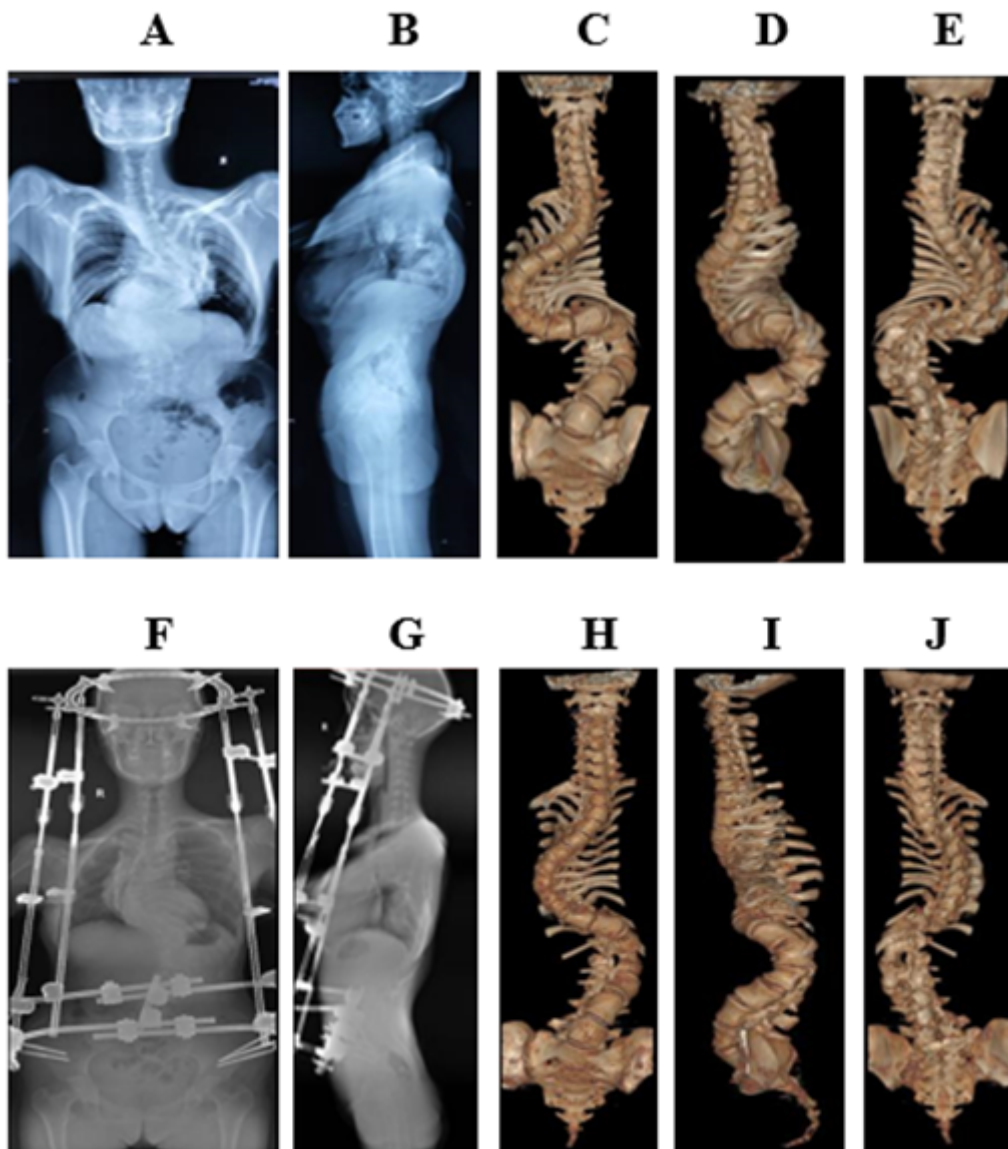
Index	Before traction	Final traction review	After internal fixation surgery	Last follow-up	F-value	P-value
FVC (L)	1.13±0.19	1.36±0.28 <sup>a</sup>	1.49±0.28 <sup>a</sup>	1.53±0.26 <sup>a</sup>	57.608	<0.001
FVC%	31.61±4.64	36.19±4.95 <sup>a</sup>	38.08±7.46 <sup>a</sup>	38.61±6.91 <sup>a</sup>	32.188	<0.001
FEV1 (L)	1.08±0.22	1.17±0.19 <sup>a</sup>	1.26±0.22 <sup>a</sup>	1.28±0.24 <sup>a</sup>	20.670	<0.001
FEV1%	29.68±11.56	33.45±5.97 <sup>a</sup>	35.91±7.81 <sup>a</sup>	36.88±7.85 <sup>a</sup>	16.550	<0.001

Compared to before towing, <sup>a</sup>P<0.01°

**Introduction to Typical Cases**

Patient Zhang, female, 25 years old. Upon admission, X-ray examination diagnosed scoliosis, kyphosis, Marfan syndrome, and pulmonary insufficiency. Preoperatively, the entire spine was displayed in both the anterior and lateral positions, with scoliosis (S) and thoracic deformities, as shown in Figure 1 (A-B); Preoperative 3D imaging of the entire spine showed scoliosis in an "S" shape, with some vertebral bodies

showing poor segmentation and deformities in the chest and ribs, as shown in Figure 1 (C-E). After 3 months of improved HPT treatment, the entire spine was displayed in both the anterior and lateral positions, and there was a significant improvement in scoliosis compared to before, as shown in Figure 1 (F-G); The 3D imaging of the entire spine shows significant improvement in scoliosis, as well as chest and rib deformities, as shown in Figure 1 (H-J).



**Figure 1:** 3D imaging of the entire spine in the anterior and lateral positions before and after modified HPT treatment, as well as the entire spine

## Discussion

Traditional HPT applications are not widely used, mainly due to inconvenient installation of HPT traction devices, low fault tolerance, and poor patient tolerance. Hai Yong [11] believes that although HPT can correct various spinal deformities through strong traction, due to the connecting rod surrounding the body and fixed position, it is difficult to avoid some spinal deformities. Even if it is reluctantly installed, it will compress the local skin and affect the traction effect. This

study used modified HPT traction therapy for patients with severe spinal deformities and respiratory dysfunction. The results showed that all imaging indicators of patients after traction (last follow-up, internal fixation surgery, and last follow-up) were lower than before traction, indicating that modified HPT traction has significantly restored overall balance in the coronal and sagittal planes, as well as local balance in the shoulder and pelvis. This is because traditional HPT is cumbersome to wear and does not allow patients to sleep on their backs, making it impossible to perform traction around the clock. The improved HPT traction rod placed on the front

and outer sides of the body can effectively avoid spinal deformities, allowing patients to sleep and dress in a supine position. It can achieve 24-hour continuous traction and provide strong traction all day, effectively correcting spinal deformities. In addition, the traditional HPT structure is relatively single, and due to differences in patient body size, personalized traction cannot be achieved. The improved pelvic ring of HPT is a half ring, which can be worn from the side, avoiding the inconvenience caused by the traditional HPT pelvic closed-loop structure being worn from the foot. At the same time, the semi-circular structure can adjust its size and shape, suitable for patients of different body types, thereby effectively improving traction efficiency and improving spinal deformities. Qi et al [12] reported that the combination of HPT and spinal release surgery can improve traction, but according to the author's report, the average corrected Cobb angle for patients after surgery is about 38.5°, slightly lower than the results of this study. However, it should be pointed out that there are obvious shortcomings in simply pursuing traction efficiency and combining spinal release surgery. Spinal release surgery can increase surgical trauma and treatment costs, while also increasing the incidence of cardiovascular and pulmonary complications [13]. Sui Wenyuan et al [14] also confirmed that rapid correction of severe spinal deformities with respiratory dysfunction not only fails to achieve the expected results, but also increases the risk of complications and mortality. Relatively speaking, improved HPT can provide strong traction and continuously act on the main curvature area of the spine, gradually improving body balance and spinal sequence, avoiding the risk of nerve damage and complications caused by violent correction. At the same time, it can also increase patient tolerance and improve comfort through relatively free positioning and convenient wearing methods.

Severe spinal deformities not only affect the appearance of patients, but when deformities occur in the thoracic vertebrae, they can cause chest collapse, spinal shortening, reduced thoracic volume, and lead to pulmonary ventilation dysfunction. However, rapid correction is not recommended for patients with severe spinal deformities and respiratory dysfunction, as violent correction can increase the risk of nerve damage, disability, and mortality [15]. The results of this study showed

that the respiratory function indicators at each stage after using modified HPT traction were significantly better than before traction, indicating that modified HPT treatment can improve the respiratory function of patients. This is because the improved HPT adopts a relatively mild adjustment method, which achieves the purpose of traction and correction of spinal deformities by intermittently adjusting the traction frame, thereby alleviating the compression of the spine on the thoracic cavity. Liu Dun et al [16] believe that although HGT can improve respiratory function in patients with severe spinal deformities, it is only suitable for young children with good flexibility in severe spinal deformities, and its effect on severe stiff spinal deformities and middle-aged and elderly patients is poor. The improved HPT uses a connecting rod between the pelvic ring and the halo ring to traction the spine, providing stable and sustainable traction without affecting patient cardiovascular exercise. The improved HPT also has the characteristics of controllability and gradual progression, with high safety. It avoids strong stimulation to the heart and lungs while slowly pulling the spine. As the spine height is elongated and the chest is formed, the corresponding chest deformity and volume are significantly improved, and the patient's lung function is also significantly improved. This study also found that the trend of respiratory function changes in patients gradually improved over time, indicating that HPT traction therapy promotes thoracic remodeling and gradually improves anterograde thoracic compliance. At the same time, HPT slow stretching of the spine is improved to match respiratory muscles with thoracic volume, and ventilation function gradually improves. Improved HPT can not only be used for preoperative correction of spinal deformities, but also for maintaining traction during surgery and facilitating the placement of internal fixation devices, as the traction frame is placed on the anterior lateral side, promoting patient recovery. Qi et al [17] also believe that for patients who are unable to install purely mechanically and have difficulty with internal fixation, HPT traction can reduce the difficulty of internal fixation installation, reduce load, and effectively prevent the risk of decoupling and rod breakage. It is an effective auxiliary treatment measure for severe spinal deformities.

In summary, the improved HPT traction treatment for patients with severe spinal deformities and respiratory dysfunction

tion can effectively correct spinal deformities, restore overall spinal balance, and improve respiratory function. It is a safe and effective auxiliary treatment measure for severe spinal deformities and respiratory dysfunction. There are the following shortcomings in this study: ①The included cases were all patients who underwent HPT treatment in the first stage and underwent corrective surgery in the second stage. Due to the inability of patients whose respiratory function did not meet the requirements after traction to undergo the second stage surgery, this study can only reflect cases of patients with significant HPT treatment effects. ②During the last follow-up pulmonary function test, the patient's spine was still in a fixed state, and the patient's forced breathing range was limited, which may affect the results of respiratory function indicators. In future research, we will conduct in-depth analysis of the relationship between the duration and timeliness of traction therapy, aiming to optimize the treatment process and improve traction efficiency of improved HPT. At the same time, we will also consider introducing comfort indicators to better promote the application of improved HPT.

## References

- Garg B, Mehta N (2020) Modified posterior vertebral column resection for severe spinal deformity: a retrospective, comparative study [J]. *Spine J*, 20: 1446-51.
- Jagger F, Tsirikos AI, Blacklock S, et al. (2020) Adaptation to reduced lung function in children and young people with spinal deformity [J]. *J Clin Orthop Trauma*, 11: 191-5.
- Lin S, Ma S, Zhou Z, et al. (2023) Improvement of pulmonary function and reconstructed 3D lung volume after deformity correction for thoracic spinal posttubercular kyphosis: a multicenter study [J]. *J Neurosurg Spine*, 39: 58-64.
- Wang Lihang, Chen Qiling, Lu Tingsheng, et al. (2022) The significance of using head pelvic ring traction to correct severe stiff spinal deformities [J]. *Chinese Journal of Orthopedics*, 30: 1704-7.
- Hu M, Lai A, Zhang Z, et al. (2021) Intraoperative halo-femoral traction during posterior spinal arthrodesis for adolescent idiopathic scoliosis curves between 70° and 100°: a randomized controlled trial [J]. *J Neurosurg Spine*, 36: 78-85.
- Shi Benlong, Li Yang, Liu Zhen, et al. (2021) Application of Halo gravity traction before corrective surgery for severe upper thoracic angular kyphosis with nerve damage [J]. *Chinese Journal of Orthopedics*, 41: 412-9.
- Sun Y, Zhang Y, Ma H, et al. (2023) Halo-pelvic traction in the treatment of severe scoliosis: a meta-analysis [J]. *Eur Spine J*, 32: 874-82.
- Zhang Yushuang, Equation, Huang Lijun, et al. (2021) Clinical effects of applying Halo pelvic traction in the treatment of severe stiff spinal deformities in adults [J]. *Journal of Orthopedic Clinical and Research*, 6: 340-5.
- McIntosh AL, Ramo BS, Johnston CE (2019) Halo Gravity Traction for Severe Pediatric Spinal Deformity: A Clinical Concepts Review [J]. *Spine Deform*, 7: 395-403.
- Yang C, Wang H, Zheng Z, et al. (2017) Halo-gravity traction in the treatment of severe spinal deformity: a systematic review and meta-analysis [J]. *Eur Spine J*, 26: 1810-6.
- Hai Yong (2019) Development History of Spinal Surgery in China [J]. *Chinese Journal of Orthopedics and Arthrology*, 8: 721-5.
- Qi L, Xu B, Li C, et al. (2020) Clinical efficacy of short-term pre-operative halo-pelvic traction in the treatment of severe spinal deformities complicated with respiratory dysfunction [J]. *BMC Musculoskelet Disord*, 21: 665.
- Du Ping, Xu Huaye, Zhu Huijie, et al. (2020) Study on the effect of red blood cell suspension pre washing method in preventing hyperkalemia during pediatric scoliosis correction surgery [J]. *Chinese Journal of Physician Continuing Education*, 43: 969-72.
- Sui Wenyuan, Liu Hanzhong, Zhang Wei, et al. (2019) The effect of Halo gravity traction on lung function in adolescent patients with severe stiff spinal deformities accompanied by respiratory dysfunction [J]. *Chinese Journal of Orthopedic and Joint Surgery*, 12: 30-4.



15. Wang J, Han B, Hai Y, et al. (2021) How helpful is the halo-gravity traction in severe spinal deformity patients?: A systematic review and meta-analysis [J]. *Eur Spine J*, 30: 3162-71.
16. Liu Dun, Li Yang, Shi Benlong, et al. (2019) Application of Halo gravity traction in patients with type I neurofibromatosis and severe scoliosis [J]. *Chinese Journal of Surgery*, 57: 119-23.
17. Qi L, Zhao Y, Xu B, et al. (2022) Two-stage treatment for severe spinal kyphotic deformity secondary to tuberculosis: halo-pelvic traction followed by a posterior-only approach correction [J]. *BMC Musculoskelet Disord*, 23: 991.

**CEOS Publishers** follow strict ethical standards for publication to ensure high quality scientific studies, credit for the research participants. Any ethical issues will be scrutinized carefully to maintain the integrity of literature.

## Publication Ethics

## Plagiarism Policy

## Copyrights

**CEOS Publishers** believes scientific integrity and intellectual honesty are essential in all scholarly work. As an upcoming publisher, our commitment is to protect the integrity of the scholarly publications, for which we take the necessary steps in all aspects of publishing ethics.

All the articles published in **CEOS Publisher** journals are licensed under Creative CommonsCC BY 4.0 license, means anyone can use, read and download the article for free. However, the authors reserve the copyright for the published manuscript.